

COST-2103

WG 5

Aachen 2008

Register measurements in puberty

By:

**Pedersen M, MD Ear-nose-throat
specialist, PhD, FRSM**

The Medical Centre, Ear-nose-throat and
Voice Unit

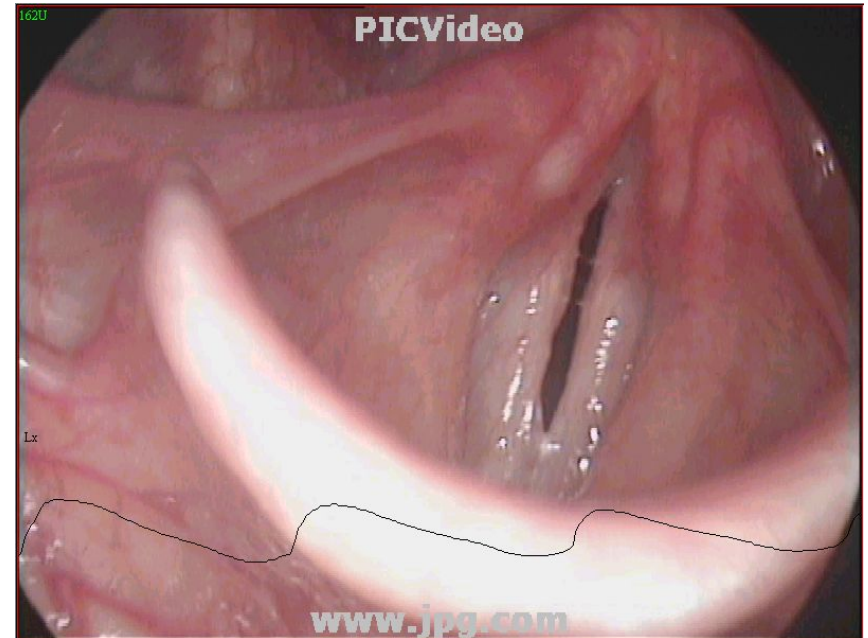
Oestergade 18

DK-1100 Copenhagen, Denmark

A Cost 2103 research study Aachen 2008

Stroboscopy

- It is hardly possible to see register shifts in pubertal boys even if there is a very clear acoustical change of a whole octave, as demonstrated in a video film at the Voice symposium 1988 in NY, USA (1).



Phonetography

- is a valuable tool to measure the tone range and the dynamic range in puberty. An example of pre-pubertal and post-pubertal boys' voices is shown (longitudinal investigation in **The Royal Danish Boys Choir**).
- In that study **the phonetograms were compared with hormonal and pubertal development**, a pubertal boy having a serum testosterone level of more than 10 nmol/l.
- Many other studies have been made on the development of voice where phonetography seemed to be the best tool.

Phonetography

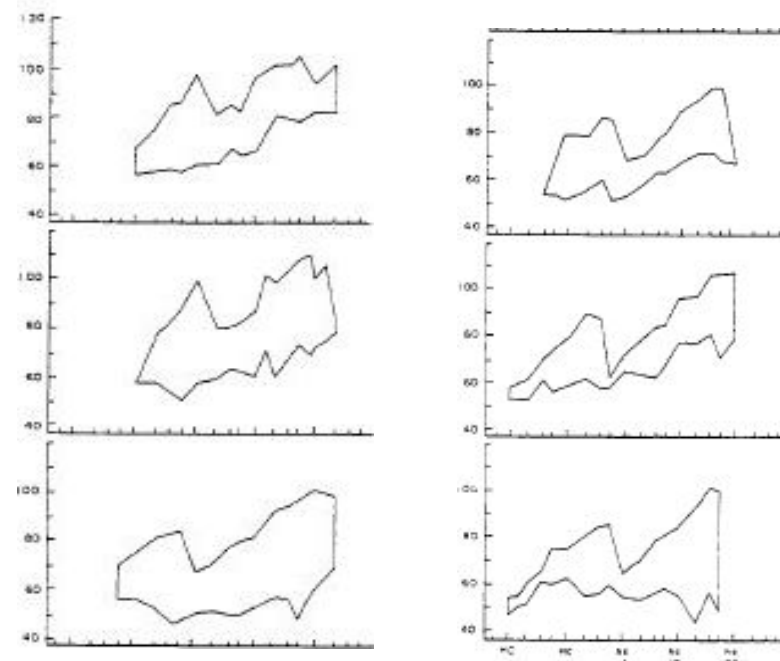
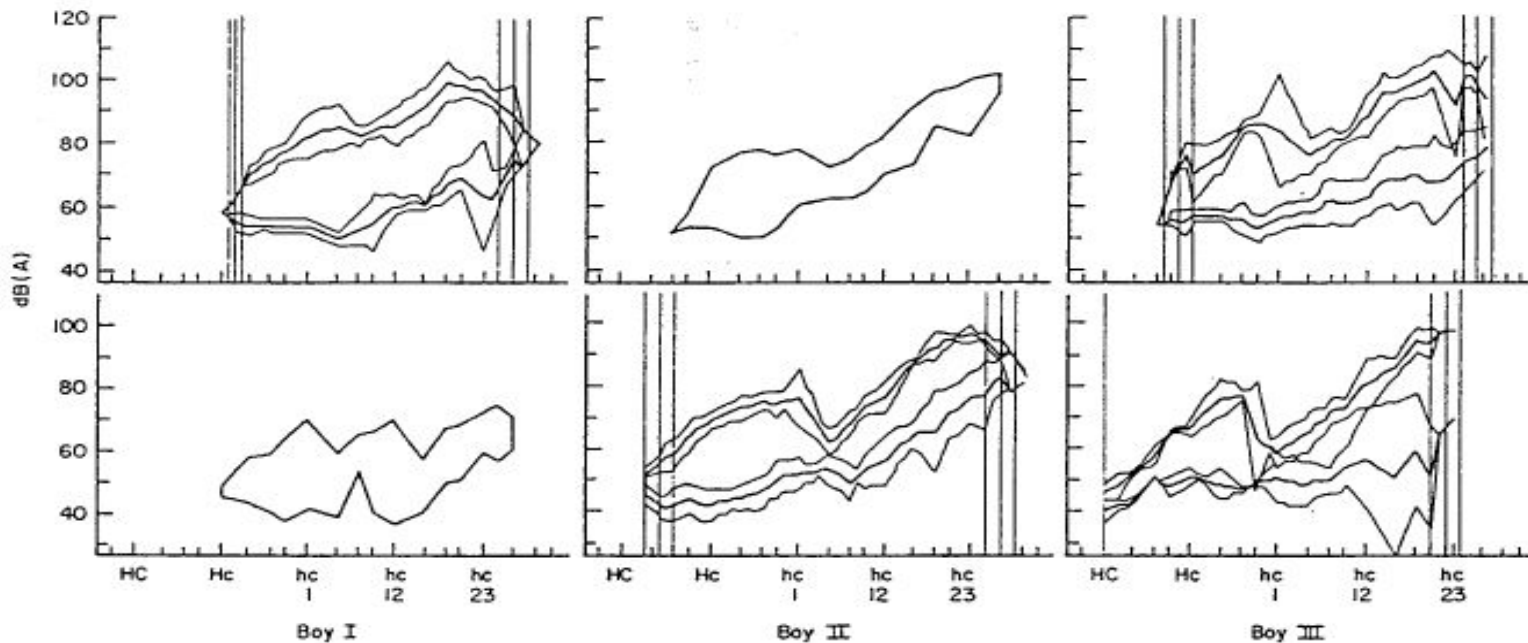


Figure 1. Six phonetograms with 2 months interval of one prepubertal boy from age 13 7/12 to 14 6/12 years. The third phonetogram (in December) was best. In January the boy was excluded from the choir (cl. 262 Hz). M Pedersen Thesis 1997

Phonetography

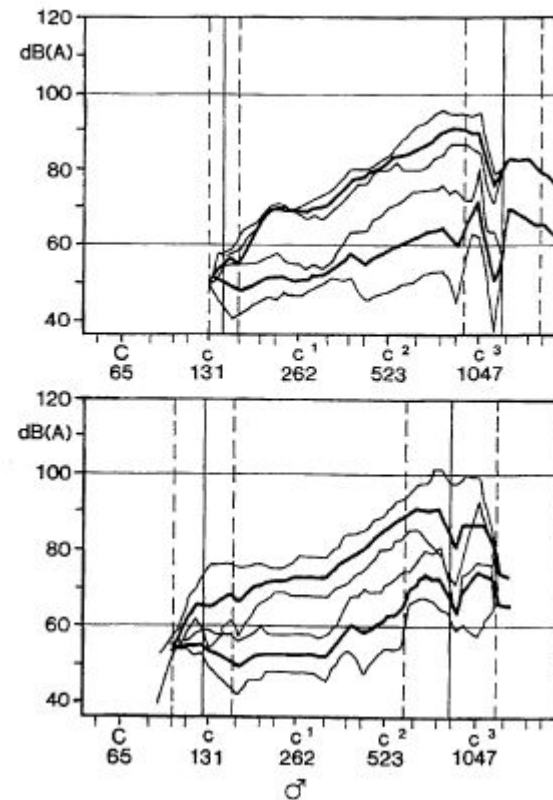
Three boys: boy one has 1 pubertal phonetogram and 5 prepubertal phonetograms, boy two has 1 prepubertal and 5 pubertal, boy three has 3 prepubertal and 3 pubertal phonetograms. The prepubertal boys were still singing in the choir.

Die biologische Entwicklung der Stimme in der Pubertät

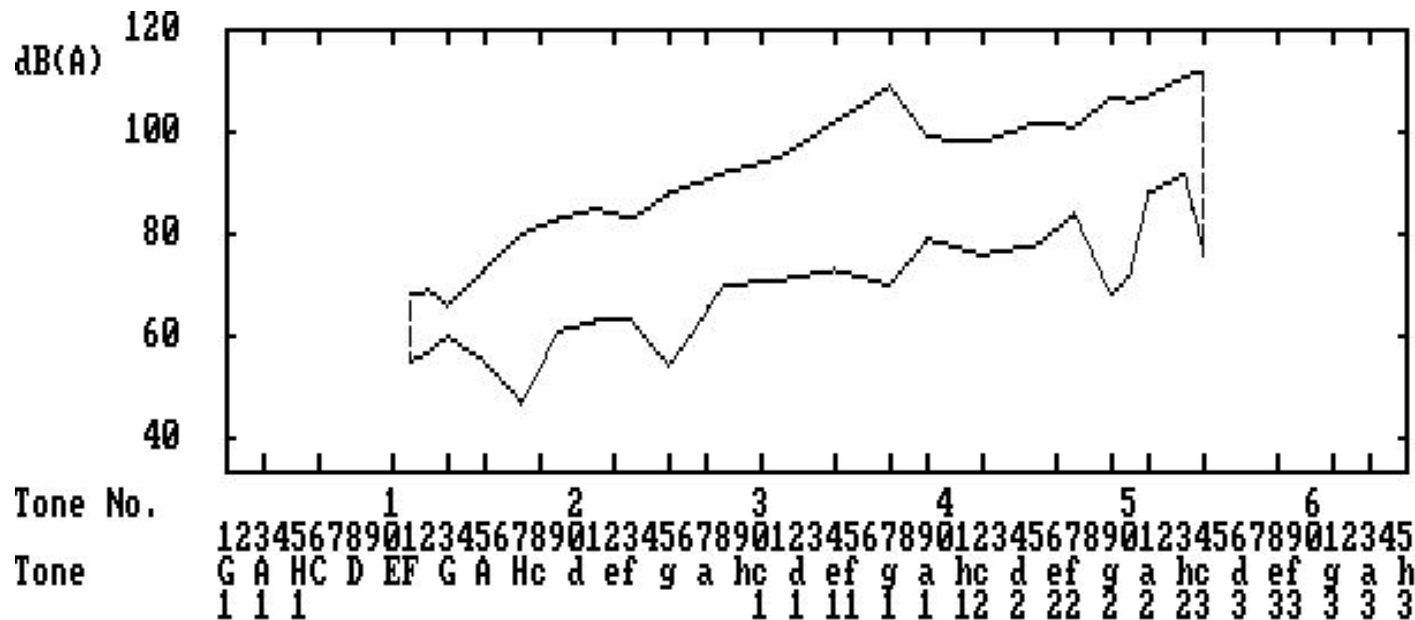


- Electrolottography is another valuable tool. The method has been used already by us in the **Thomaner choir in Leipzig**.
- This is underlining the register shifts seen in the phonetograms.

Die biologische Entwicklung der Stimme in der Pubertät



This is a phonetogram of a 17 year old male singer



1. Save recording on disk.
2. Print recording as chart.
3. Print recording in table.
- X. Return to main menu.
- Select function.

Name
 Area 1069 dB x semitones
 Dynamic range 0039 dB
 Lowest tone F = 87.3 Hz
 Highest tone c3 = 1047 Hz
 Identification A:010890.01

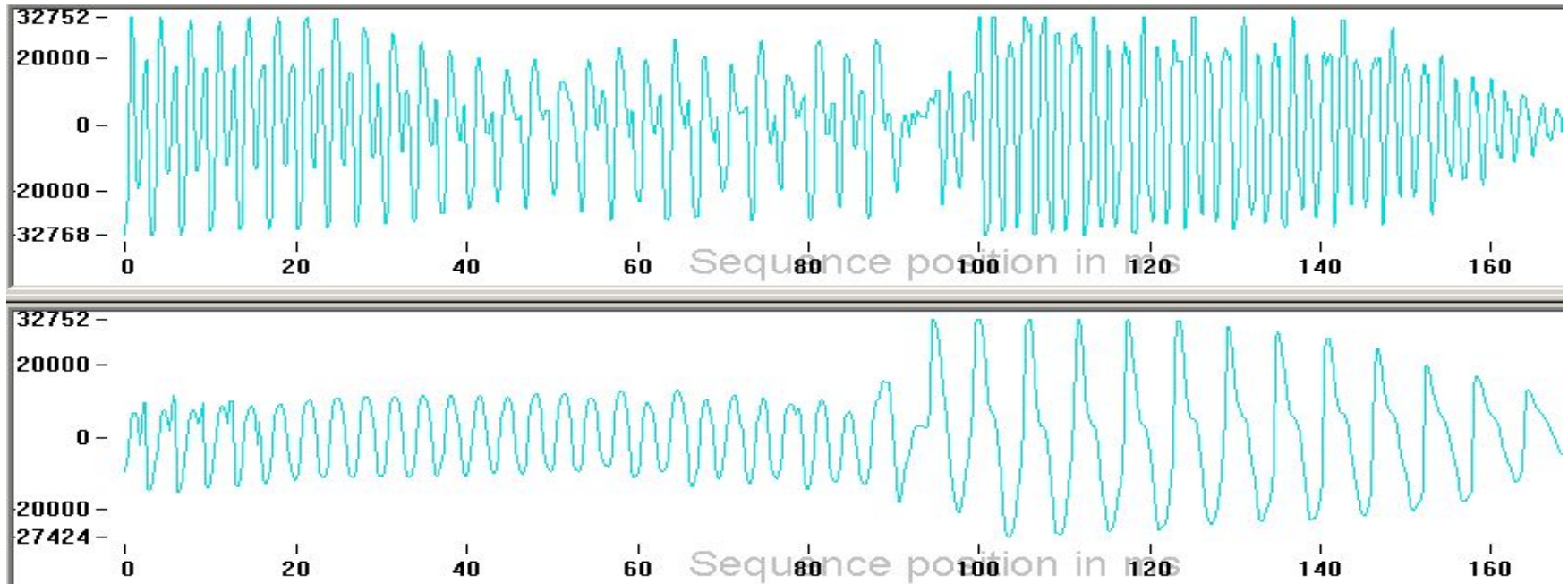
The new tool:

High-speed films

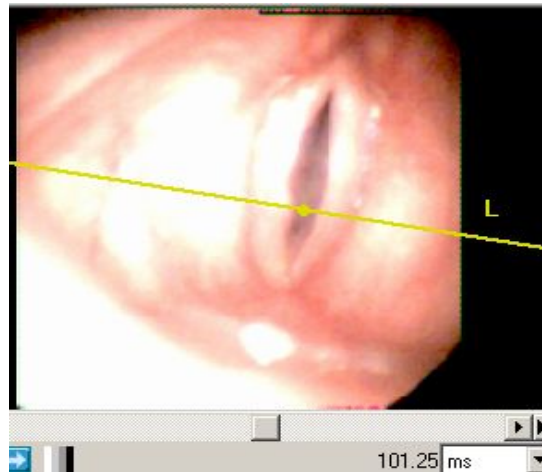

- compared with *acoustical measurements, electroglottography and kymography* show very interesting differences between the acoustical and electroglottical measurements in our example.
- **The example with phonetography includes the two upper registers with phonetograms (of childhood), and the two lower registers (of an adult) of a 17-year old boy, and the upper register shift is seen electroglottographically at 500 Hz.**

Acoustically around 10 cycles are changed before the electrglottographic register shift.

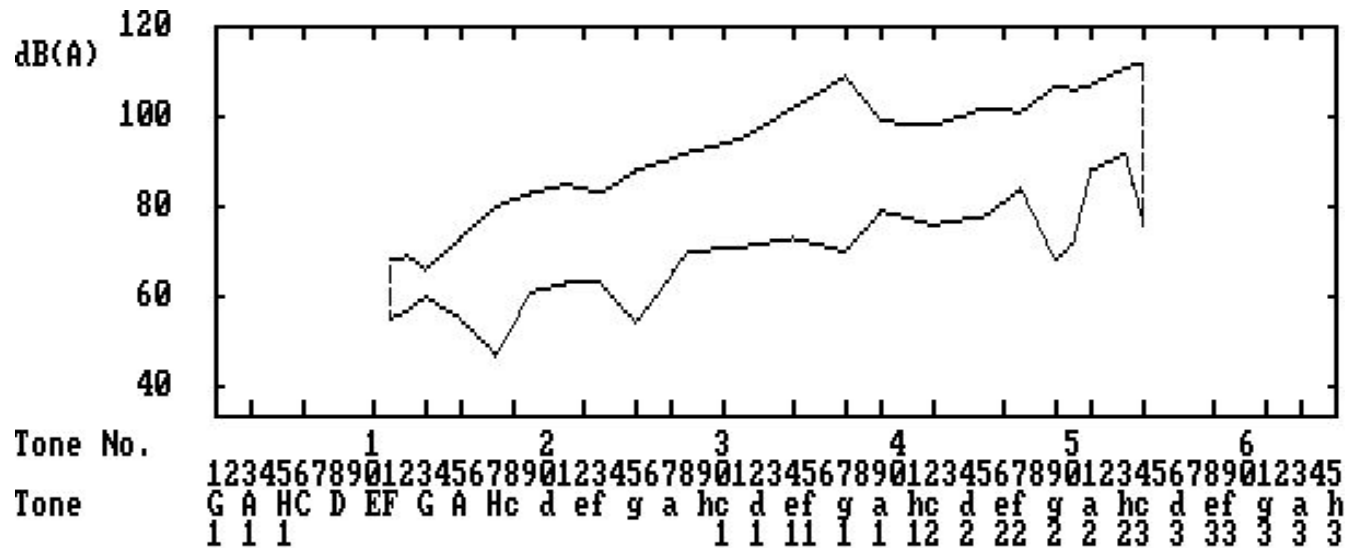
- The analysis were made in the middle of the vocal cords with 4000 pictures/sec. (Wolf inc.). The acoustical change is related to the tuning of the upper vocal tract.



The kymographic film corresponds to the electroglottographical picture.



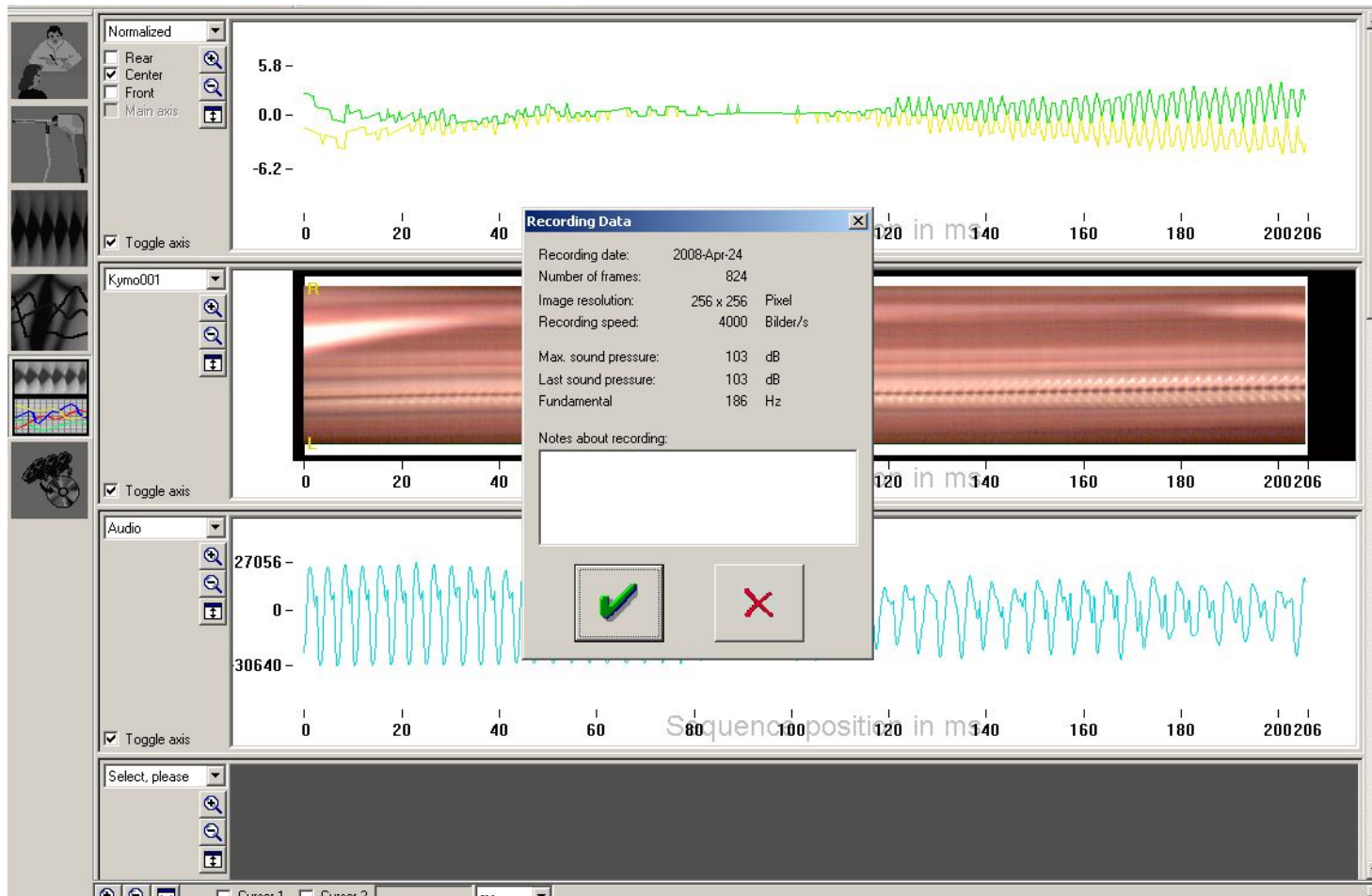
The earlier shown register shift of the male singer was at 502 Hz. We now present some data from the low register shift at 186 Hz.

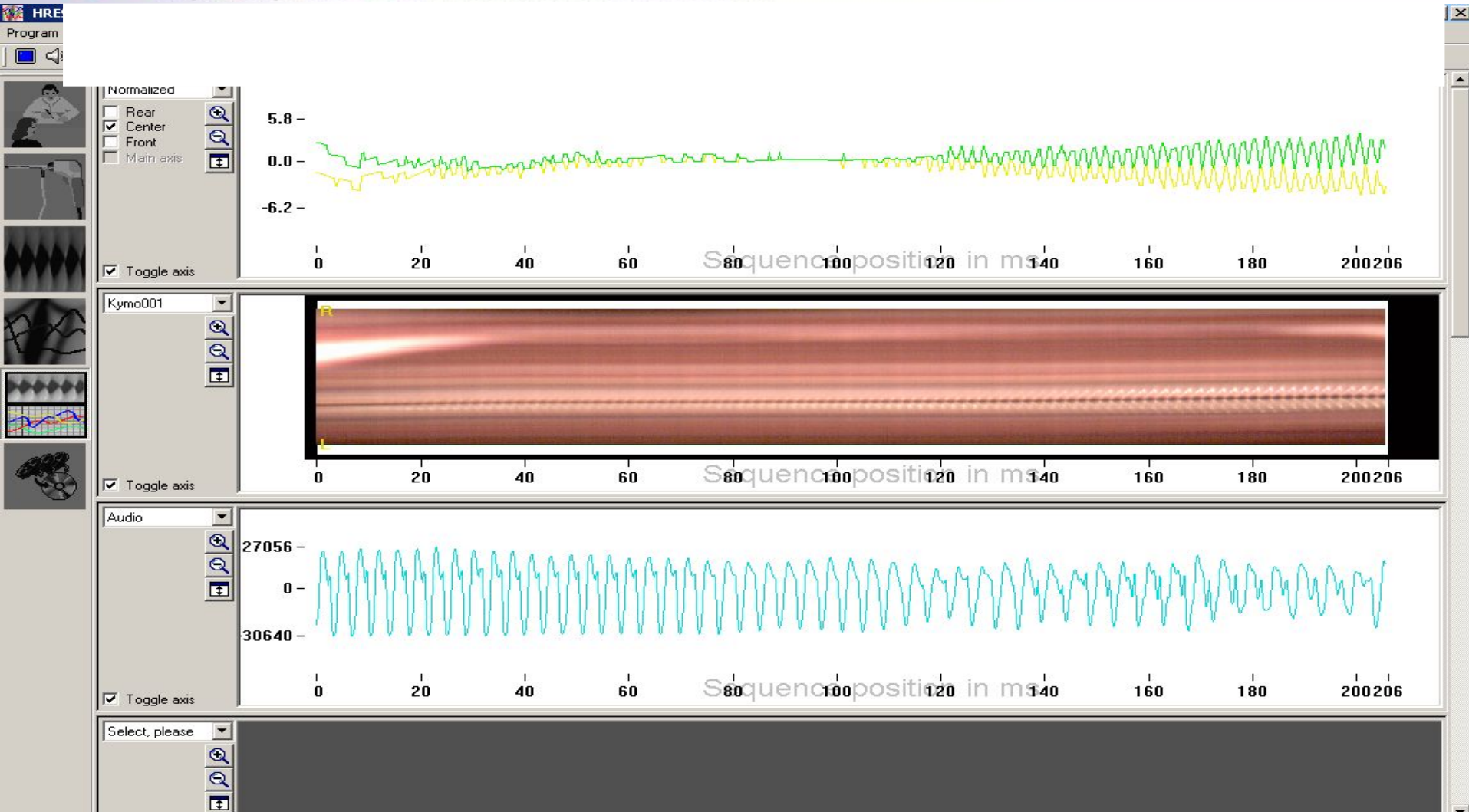


1. Save recording on disk.
2. Print recording as chart.
3. Print recording in table.
- X. Return to main menu.
- Select function.

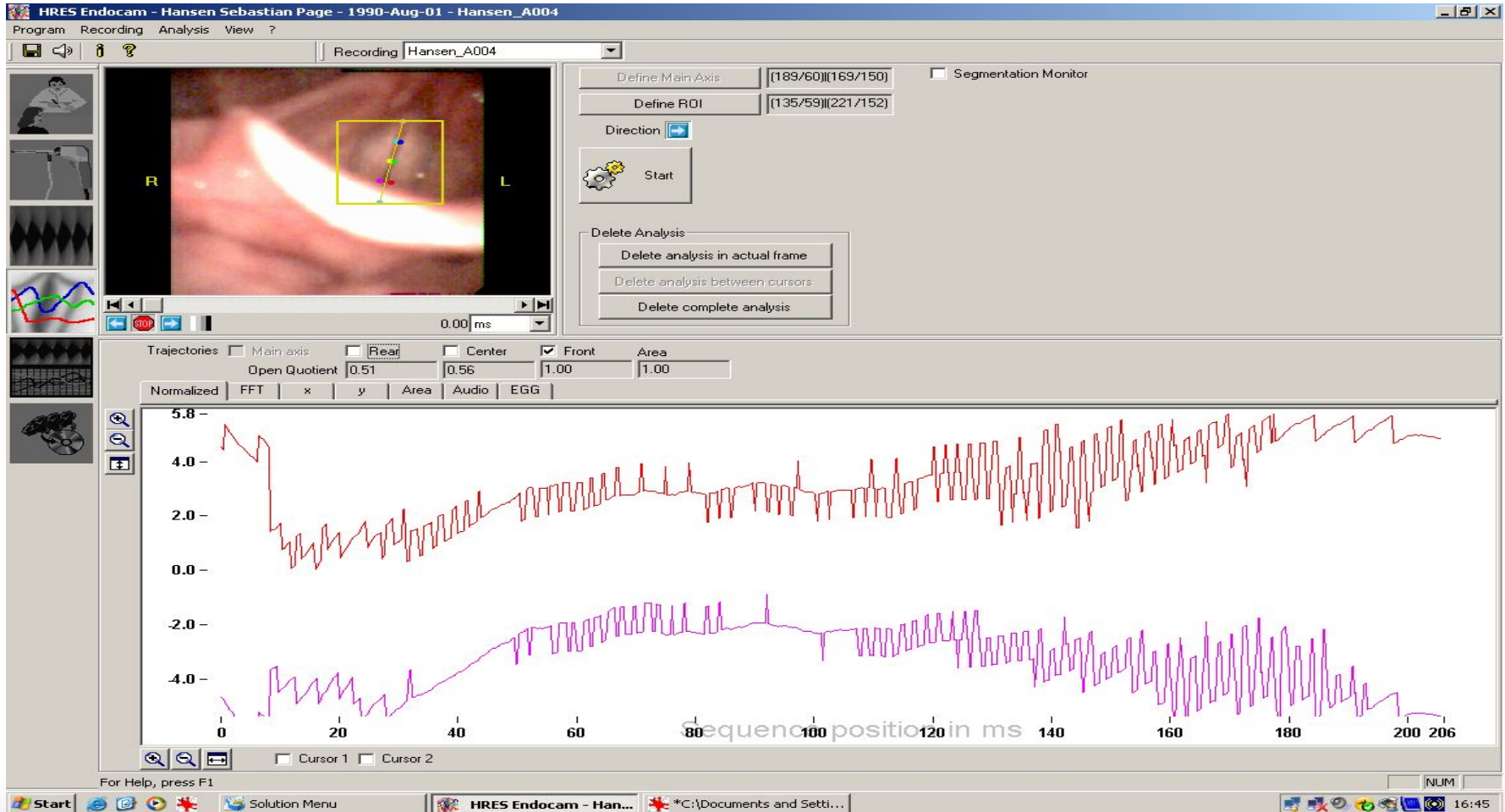
Name
Area 1069 dB x semitones
Dynamic range 0039 dB
Lowest tone F = 87.3 Hz
Highest tone c3 = 1047 Hz
Identification A:010890.01

- On the next slide we will show you the center movements of the vocal chords register change (**upper curve**)
- compared with the kymograms (**middle curve**)
- and the acoustical registration (**lower curve**).

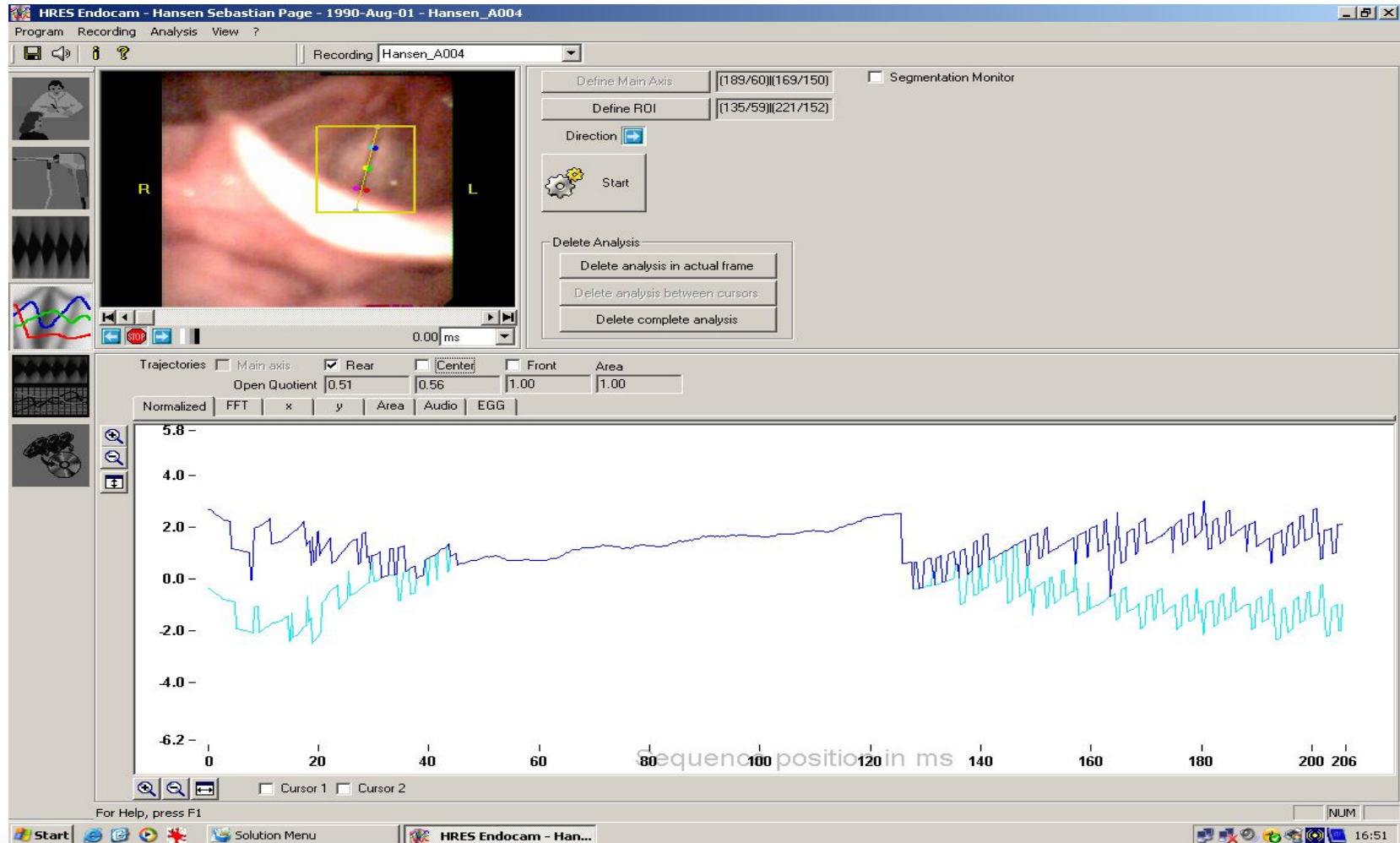




The front part of the high-speed film shows no connection between the vocal chords



The rear part of the high-speed film shows connection between the vocal chords.



References

- 1. Pedersen M(F), Hacki,T, Loebell E (1988) Videostroboscopy of choir boys in puberty (film). Ed. Medizinische Hochschule Hannover. Germany.
- 2. Pedersen M(F) (1993). A longitudinal pilot study on phonetograms/voice profiles in prepubertal choir boys. Clin otolaryngol; 18 84-9.
- 3. Pedersen M (1997). Biological development and the normal voice in puberty. Thesis. Univ. Oulu. (<http://mpedersen.org>)