

# **Future aspects of cellular and molecular research in clinical voice treatment aspects of optical coherence tomography**

Mette Pedersen MD, Sanila Mahmood Pharm.stud.

The Medical Centre, The Voice Unit, Oestergade 18, 3, 1100 Copenhagen, Denmark.

## **ABSTRACT**

Focus is upon our clinical experience in a prospective cohort study on cure of dystonia where the mode of treatment was fexofenadine tablets and local budesonide inhaler in the larynx, and in a randomized controlled trial of lifestyle change related to acid provocation of food and habits in laryngopharyngeal reflux (LPR). The advanced high-speed films is one new tool, another being optical coherence tomography (OCT), which should be used in the future in randomized controlled trials.

We are focusing on OCT of the swallowing process in the oesophagus and larynx as well as the vocal fold function. It can be shown on OCT how the layer of the vocal folds develop, possibly corresponding to hormonal and paediatric development. The arytenoid area in the larynx should also be focused upon with OCT in pathology. The thyroid function is related to voice and the swallowing function, both hormonally and pathoanatomically. We know too little about voice and thyroid hormones in an updated way as well as the outer anatomic supporting muscular structure of the larynx, related to thyroid immune degeneration and cysts. Also, here OCT analyses might be of value.

## **Keywords**

Optical coherence tomography, voice, pharmacogenetics.

## **1. Introduction**

This paper is based on questions arisen in our research and clinical experience treating benign laryngeal disorders. The genetic aspects on benign and malignant laryngological disorders are discussed [1] Until now we have no understanding on a cellular or molecular level of normal voice function. Social / psychological aspects on one side and some surgical / physiological aspects on the other side have been elucidated. We had an opportunity, in a review in the Cochrane institution of evidence based randomized control trials to make a survey of vocal nodules, which are destroying the voice function of many singers [2]. This survey has been updated from 2001 to 2012 and until now there is no evidence of surgery or speech therapy. With our knowledge of high speed films we made another Cochrane review of laryngopharyngeal reflux (LPR) showing no evidence of treatment [3]. With video stroboscopy based on average of 25 pictures pr. second there were many descriptions in the literature of various kinds of larynx disorders, which were not found on high speed films with 4,000 pictures pr. second (Table 1[4]). LPR as a symptomatic entity was therefore questioned and a new setup was suggested for description of the larynx findings in LPR based on graduation of oedema in the arytenoid regions in the larynx (Figure 1 [5]).

A randomized controlled trial of LPR showed that the diet correction without acid provocations in the larynx based on lifestyle change was essential, the supplementary use of proton pump inhibitor not being better [6]. We noticed that the use of fexofenadine tablets and budesonide inhaler had a supplementary effect on the swollen mucosa in the upper airways – due to a direct effect in the upper airways (Figure 2 [7]).

## 2. Questions

A young female patient came into the clinic with hoarseness and universal dystonia sent by her physiotherapist for her hoarseness. She had been on pension one and a half year and was sitting in a wheelchair. We used the high speed films to document the vocal spasms due to her dystonia and gave her local budesonide inhaler as well as fexofenadine tablets in maximal doses, as we earlier experienced with LPR treatment (Figure 3 [8]). Two weeks later she came walking in without hoarseness and dystonia symptoms. She later had recurrent symptoms provoked by acute tonsillitis. After this experience we made a prospective cohort study which showed on average a reduction of dystonia symptoms of 20 percent using fexofenadine tablets and local budesonide inhalers in the throats of the patients. Of course we thought that a genetic effect somehow was involved in the treatment. The cohort study (Table 2, Figure 4 [8]) involved two comparable groups of patients with normal / low mannose binding lectin (MBL). There was no statistical difference. In this study, our research focus was on fexofenadine tablets in high doses (2-3 times daily doses) and local budesonide inhalers in the larynx in maximal used doses. We found a statistical significant reduction of oedema of the arytenoid region, also on spasmodic symptoms. Genetic studies in the population in the cohort study did not give significant relations.

Gastro esophageal reflux disorder (GERD) is known to be inherited. In the cohort study [8] no pattern was found of this genetic aspect. Still the genomic questions are whether primary/secondary dystonia have special relations to fexofenadine tablets or budesonide inhaler locally in the larynx [9-11]. The genome analysis in the patients is time consuming, some exons that express dystonia could be focused upon for locating genes related to fexofenadine tablets, and budesonide inhalers in the larynx. Probably parents, sisters and brothers must be focused upon also, for understanding genetic relationships [12].

Studies on molecular and cellular levels related to the clinical results in voice treatment are needed. There is a known relationship in the literature of dystonia and mucosal function in the larynx. In animals it was shown that excision of the larynx mucosa provokes dystonia [13]. Most studies of budesonide inhalers are made in the lower airways, of course not allowing us to extrapolate to the upper airway, where the effect theoretically is to be related to a laryngeal effect. The fexofenadine tablet treatment is related to the immune system, blocking reactions to attacks from outside, also with other means than antihistamine activity [14,15]. It is well known that fexofenadine tablets are effective on the inhabitancy of oedema of the mucosa [16,17]. An understanding on a genetic level is of major interest in a new genomic research setup in Oxford [18]. The principal effect of fexofenadine tablets in the referred cohort study seemed to be that some mucosal voice related functions came under control.

## 3. Analyses

Until now even high speed films [4] of the vocal folds and the arytenoid region mucosa has not given us any explanation for the medical effect, reducing LPR or dystonia. The vocal fold over all gross anatomy was always normal. We can see on the high speed films that in LPR there is a lack of closure of the back of the vocal folds and oedema of the arytenoid region involved, and in dystonia patients' irregularities of rhythm in single movements of the vocal folds. We can also see on high speed films that the pathology disappears or is reduced with fexofenadine tablets and budesonide inhalers in the larynx [6, 8]. Advanced computer reproduction of the single movement of the vocal folds might give more information to be used in the future with stiffness analysis ([19] figure 5).

We are focusing on optical coherence tomography (OCT) of the swallowing process in the oesophagus and larynx as well as on the vocal fold function [20-22]. It can be shown on OCT how the layers of the vocal folds develop, possibly corresponding to hormonal and paediatric development [23, 24]. The arytenoid area in the larynx should be focused upon with OCT in pathology.

The thyroid function is related to voice and the swallowing function, both hormonally and pathoanatomically. We know too little about voice and thyroid hormones in an updated way as well as the outer anatomic supporting muscular structure of the larynx, related to thyroid immune degeneration and cysts [25-26]. Also here OCT analyses might be of value.

### 3.1 Problems to be solved with optical coherence tomography

- A) Identification of laryngeal tissue abnormalities, especially grading of edema of the arytenoid region:

Burns et al. showed imaging of the mucosa of the human vocal folds with optical coherence tomography [27]. Wong et al. used in vivo optical coherence tomography of the human larynx and gave normative descriptions and benign pathology in 82 patients [28]. Burns et al. tried real time tracking of vocal folds injections with optical coherence tomography [29]. Just et al. showed that optical coherence tomography of larynx identification of laryngeal epithelial dysplasia for precise biopsy in 61 patients during microlaryngoscopy [30, 31]. Pictures of intraoperative OCT were presented by the firm OPMed. Kobler et al. presented dynamic imaging of vocal folds oscillation with four-dimensional optical coherence tomography [32, 33]. Burns et al. showed a more advanced polarization-sensitive optical coherence tomography imaging of benign and malignant laryngeal lesions in an in vivo study [34]. For multiple use aspect for quantitative upper airway endoscopy Wijesundara et al. used swept-source anatomical optical coherence tomography [35].

- B) Identification of non-laryngeal upper airway related tissue, where some results have been made:

Optical coherence tomography is used in cardiology, and there is an international working group on intravascular aspects including coronary disease and sub pleural alveolar size parameters. Histogram analysis of lipid-core plaques in coronary computed tomographic angiography is also made, interesting aspect are detection of lipid using spectroscopic optical coherence tomography [36-41].

As for upper airway, methods are being developed for quantitative study of airway functional anatomy using OCT [42], and correlation has been found between ex vivo pulmonary specimens and OCT [43]. Focus is also on cystic fibrosis [44]. For esophagus studies there is inter observer agreements for the detection of Barrett's esophagitis with OCT [45]. Esophageal-guided biopsy has been made with OCT [46]. An overview is given of the advances in gastrointestinal imaging [47]. For studies of lungs and OCT, pulmonary nodules are being identified with OCT [48], and for aspects of thyroid, OCT imaging is being used for tissue identification and differentiation [49].

Technical aspects of optical coherence tomography:

OCT as a principle is under development. The problem seems to be to focus correctly with enough light and stabilize the probe locally [50-56].

### 4. Discussion and conclusion

The aim of this overview was to elucidate voice problems related to molecular and cellular research based on evidence findings. Since no evidence was found in the referred Cochrane reviews on vocal nodules and hoarseness and on laryngo pharyngeal reflux and hoarseness, the focus was on clinical experience in a prospective cohort study on dystonia where the treatment was fexofenadine tablets and local budesonide inhaler in the larynx, and in a randomized controlled trial of lifestyle change related to acid provocation of food and habits in LPR. The advanced high speed films are one new tool, the other OCT to be used in randomized controlled trials. With molecular and cellular knowledge on fexofenadine tablets and budesonide inhaler and to some extent diet, clinical trials of voice in the future could include the molecular and cellular understanding in a much better way. Better genetic pathways understanding should also be focused upon.

**5. Acknowledgement.** The medical students at Copenhagen University: Anders Jønsson and Anne Alexius Agersted helped preparing the manuscript.

## 6. References

- [1] Pedersen M. Future aspects of cellular and molecular research in clinical voice treatment. *Advances in cellular and molecular otolaryngology* 2014, 2: 24442 – <http://dx.doi.org/10.3402/acmo.v2.24442>
- [2] Pedersen M, McGlashan J. Surgical versus non-surgical interventions for vocal cord nodules (Review), *The Cochrane Library*. Cochrane review. Collaboration. The Cochrane Library 2001, updated 2012; 6.
- [3] Hopkins C, Yousaf U, Pedersen M. Acid Reflux Treatment for Hoarseness. Cochrane review. The Cochrane Collaboration. The Cochrane Library 2006, updated 2009; 1.
- [4] Pedersen M, Jønsson A. Video Stroboscopy compared with high speed films of pathological vocal folds. *J. of Community Medicine & Health Education*: 2015 in press. <http://dx.doi.org/10.4172/2161-0711.1000320>
- [5] Pedersen M, Munck K. A prospective case-control study of jitter%, shimmer% and Qx%, glottis closure cohesion factor (Spead by Laryngograph Ltd.) and Long Time Average Spectra. Congress report Models and analysis of vocal emissions for biomedical applications(MAVEBA). 2007; 60-4.
- [6] Pedersen M, Eeg M. Laryngopharyngeal Reflux – A Randomized Clinical Controlled Trial. *Otolaryngol.* 2012; S1:004. doi:2161-119X.S1-004.
- [7] Johnston N, Yan JC, Hoekzema CR, Samuels TL, Stoner G, Blumin JH, Bock JM. Pepsin promotes proliferation in normal and transformed laryngopharyngeal epithelial cells. *Laryngoscope* 2012; 122(6): 1317-1325.
- [8] Pedersen M, Eeg M. Does treatment of the laryngeal mucosa reduce dystonic symptoms? A prospective clinical cohort study of mannose binding lectin hhh other immunological parameters with diagnostic use of phonatory function studies. *European Archives of Otorhinolaryngology.* 2012; 269(5): 1477-1482.
- [9] Kubo N, Senda M, Ohsumi Y, Sakamoto S, Matsumoto K, Tashiro M, Okamura N, Yanai K. Brain histamines H1 receptor occupancy of loratadine measured by positron emission topography: comparison of H1 receptor occupancy and proportional impairment ratio. 2011; 26(2):133-9.
- [10] Kavanagh JJ, Grant GD, Anoopkumar-Dukie S. Low dosage promethazine and loratadine negatively affect neuromotor function. 2012; 123(4): 780-6.
- [11] Naicker P, Presnata S, anoopkumar-Dukie GD, Kavanagh JJ. The effect of antihistamines with varying anticholinergic properties on voluntary and involuntary movement. *Clin neurophysiol.* 2013; 124(9): 1840-1845.
- [12] Pedersen M. Chapter 1.1.18, Genetics, *European Manual of Phoniatics.* in press, ed. Springer Verlag. 2014.
- [13] Ludlow CL. Treatment for spasmodic dysphonia: limitations of current approaches. *Curr Opin Otolaryngol Head Neck Surg.* 2009; 17(3): 160–165.
- [14] Ashenager MS, Grgela T, Aragane Y, Kawada A. Inhibition of Cytokine-Induced Expression of T-Cell Cytokines by Antihistamines. *J Investig Allergol Clin Immunol.* 2007; 17(1): 20-26.
- [15] Vancheri C, Mastruzzo C, Tomaselli V, Bellistri G, Pistorio MP, Greco LR, Salinaro ET, Failla M, Contrafatto MR, Crimi N. The effect of fexofenadine on expression of intracellular adhesion molecule 1 and induction of apoptosis on peripheral eosinophils. *Allergy and Asthma Proceedings.* 2005; 26 (4): 292-298.
- [16] Davies RJ, Devalia JL. Anti-allergic properties of antihistamines in humans. *Revue Française d'Allergologie et d'Immunologie Clinique.* 1998; 38 (10): 925–930.
- [17] Botturi K, Magnan A. Histamine: A new T lymphocyte cytokine?. *Revue Francaise d'Allergologie et d'Immunologie Clinique.* 2006; 46 (7): 640-646.
- [18] 1000 Genomes project consortium. A map of human genome variation from population-scale sequencing. *Nature.* 2010; 467: 1061–1073. doi:10.1038/nature09534.
- [19] Voigt D, Döllinger M, Braunschweig T, Yang A, Eysholdt U, Lohscheller J. Classification of functional voice disorders based on phonovibrograms. *J Artificial Intelligence in Medicine.* 2010; 49(1): 51-59.
- [20] Avanki MRN, Cernat R, Tadrous PJ, Tatla T, Podoleanu AG, Hojjatoleslami SA. Spatial Compounding Algorithm for Speckle Reduction of Dynamic Focus OCT Images. *IEEE photonics Technology Letters.* 2013; 25(15).
- [21] Podoleanu AG. Optical coherence tomograph., *Brit. J. Radiol.* 2005; 78: 976-988.
- [22] Gora MJ, Sauk JS, Carruth RW, Gallagher KA, Suter MJ, Nishioka NS, Kava LE, Rosenberg M, Bouma BE, Tearney GJ. Tethered capsule endomicroscopy enables less invasive imaging of gastrointestinal tract microstructure. *Nature Medicine.* 2013; 19:238–240. doi:10.1038/nm.3052.
- [23] Maturo S, Benboujja F, Boudoux C, Hartnick C. Quantitative distinction of unique vocal fold subepithelial architectures using optical coherence tomography. *Ann Otol Rhinol Laryngol.* 2012; 121(11): 754-60.
- [24] Pedersen M. *Development of voice in childhood.* ed. Springer Verlag, 2009.

- [25] Klapperich C, Rosen J. Optically guided cancer diagnosis of thyroid nodules. CIMIT Boston University School of medicine. 2009.
- [26] Holler T, Anderson J. Prevalence of voice & swallowing complaints in pre-operative thyroidectomy patients: a prospective cohort study. *Le Journal d'oto-rhino-laryngologie et de chirurgie cervico-faciale* 2014; 43.1:48.
- [27] Burns JA, Zeitels SM, Anderson RR, et. al. (2005) Imaging the mucosa of the human vocal fold with optical coherence tomography, *Ann Otol Rhinol Laryngol*; 114(9):671-6.
- [28] Wong BJ, Jackson RP, Guo S, et. al. (2005), In vivo optical coherence tomography of the human larynx: normative and benign pathology in 82 patients, *Laryngoscope*; 115(11):1904-11.
- [29] Burns JA, Kim KH, Kobler JB, et. al. (2009) Real-time tracking of vocal fold injections with optical coherence tomography, *Laryngoscope*; 119(11):2182-6. doi: 10.1002/lary.20654.
- [30] Just T, Lankenau E, Hüttmann G, et. al. (2009), Intraoperative OCT application with an operating microscope, *Laryngology & Otolaryngology*; 123:1027-1030. Doi:10.1017/S0022215109004770.
- [31] Just T, Lankenau E, Prall F, et. al. (2010), Optical coherence tomography allows for the reliable identification of laryngeal epithelial dysplasia and for precise biopsy: A clinicopathological study of 61 patients undergoing microlaryngoscopy, *Laryngoscope*; 120(10):1964-70. doi: 10.1002/lary.21057.
- [32] Kobler JB, Chang EW, Zeitels SM, et. al. (2010), Dynamic imaging of vocal fold oscillation with four-dimensional optical coherence tomography, *Laryngoscope*; 120(7):1354-62. doi: 10.1002/lary.20938.
- [33] Liu G, Rubinstein M, Saidi A, et. al. (2011), Imaging vibrating vocal folds with a high speed 1050 nm swept source OCT and ODT, *Opt Express*; 19(12):11880-9. doi: 10.1364/OE.19.011880.
- [34] Burns JA, Kim KH, deBoer JF, et. al. (2011), Polarization-sensitive optical coherence tomography imaging of benign and malignant laryngeal lesions: an in vivo study, *Otolaryngol Head Neck Surg*; 145(1):91-9. doi: 10.1177/0194599811403078.
- [35] Wijesundara K, Zdanski C, Kimbell J, et. al. (2014), Quantitative upper airway endoscopy with swept-source anatomical optical coherence tomography, *Biomed Opt Express*; 19;5(3):788-99. doi: 10.1364/BOE.5.000788.
- [36] Olzowy B, Starke N, Schuldt T, et. al. (2013), Optical coherence tomography and confocal endomicroscopy for rhinologic pathologies: a pilot study, *Biomed Opt*; 880505.
- [37] Tearney GJ, Regar E, Akasaka T, et. al. (2012), Consensus standards for acquisition, measurements, and reporting of intravascular optical coherence tomography studies: a report from the International Working Group for Intravascular Optical Coherence Tomography Standardization and Validation, *J Am Coll Cardiol*; 59(12):1058-72. doi: 10.1016/j.jacc.2011.09.079.
- [38] Jamil Z, Tearney G, Bruining N, et. al. (2013), Interstudy reproducibility of the second generation, Fourier domain optical coherence tomography in patients with coronary artery disease and comparison with intravascular ultrasound: a study applying automated contour detection, *Int J Cardiovasc Imaging*; 29(1):39-51. doi: 10.1007/s10554-012-0067-8.
- [39] Unglert CI, Warger WC, Hostens J, et. al. (2012), Validation of two-dimensional and three-dimensional measurements of subpleural alveolar size parameters by optical coherence tomography, *J Biomed Opt*; 17(12):126015. doi: 10.1117/1.JBO.17.12.126015.
- [40] Schlett CL, Maurovich-Horvat P, Ferencik M, et. al. (2013), Histogram analysis of lipid-core plaques in coronary computed tomographic angiography: ex vivo validation against histology, *Invest Radiol*; 48(9):646-53. doi: 10.1097/RLL.0b013e31828fdf9f.
- [41] Fleming CO, Eckert J, Halpern EF, et. al. (2013), Depth resolved detection of lipid using spectroscopic optical coherence tomography, *Biomed Opt Express*; 5;4(8):1269-84. doi: 10.1364/BOE.4.001269.
- [42] Liu L, Chu KK, Houser GH, et. al. (2013), Method for quantitative study of airway functional microanatomy using micro-optical coherence tomography, *PLoS One*; 8(1):e54473. doi: 10.1371/journal.pone.0054473.
- [43] Hariri LP, Applegate MB, Mino-Kenudson M, et. al. (2013) Optical frequency domain imaging of ex vivo pulmonary resection specimens: obtaining one to one image to histopathology correlation, *J Vis Exp*; 22;(71). pii:3855. doi: 10.3791/3855.
- [44] Birket SE, Chu KK, Liu L, et. al. (2014), A functional anatomic defect of the cystic fibrosis airway, *Am J Respir Crit Care Med*; doi: 10.1164/rccm.201404-0670OC.
- [45] Sauk J, Coron E, Kava L, et. al. (2013), Interobserver agreement for the detection of Barrett's esophagus with optical frequency domain imaging, *Dig Dis Sci*; 58(8):2261-5. doi: 10.1007/s10620-013-2625-x.

- [46] Suter MJ, Gora MJ, Lauwers GY, et. al. (2014), Esophageal- guided biopsy with volumetric laser endomicroscopy and laser cautery marking: a pilot clinical study, *Gastrointest Endosc*; 79(6):886-96. doi: 10.1016/j.gie.2013.11.016.
- [47] Kirtane TS, Wagh MS, (2014), Endoscopic optical coherence tomography (OCT): Advances in gastrointestinal imaging, *Gastroenterol Res Pract*; 2014:376367. doi: 10.1155/2014/376367.
- [48] Hariri LP, Mino-Kenudson M, Applegate MB, et. al. (2013) Toward the guidance of transbronchial biopsy: identifying pulmonary nodules with optical coherence tomography, *Chest*; 144(4):1261-8. doi: 10.1378/chest.13-0534
- [49] Conti de Freitas LC, Phelan E, Liu L, et. al. (2013), Optical coherence tomography imaging during thyroid and parathyroid surgery: A novel system of tissue identification and differentiation to obviate tissue resection and frozen section, *Head Neck*; doi: 10.1002/hed.23452.
- [50] Oh WY, Yun SH, Vakoc BJ, et. al. (2008), High-speed polarization sensitive optical frequency domain imaging with frequency multiplexing, *Opt Express*; 16(2):1096-103.
- [51] Kim KH, Park BH, Maguluri, et. al. (2007), Two-axis magnetically-driven MEMS scanning catheter for endoscopic high-speed optical coherence tomography, *Opt Express*; 15(26):18130-40.
- [52] Pierce MC, Hyle PB, Cense B, et. al. (2002), Simultaneous intensity, birefringence, and flow measurements with high-speed fiber-based optical coherence tomography, *Opt Lett*; 1;27(17):1534-6.
- [53] Chang EW, Kobler JB, Yun SH, (2011), Triggered optical coherence tomography for capturing rapid periodic motion, *Sci Rep*; 2011;1:48. doi: 10.1038/srep00048.
- [54] Huang D, Swanson EA, Lin CP, et al. (1991), Optical coherence tomography, *Science*; 22;254(5035)1178-81.
- [55] Duan C, Sun J, Samuelson S, et al. (2013), Probe alignment and design issues of microelectromechanical system based optical coherence tomography endoscopic imaging, *Appl Opt*; 10;52(26):6589-98. doi: 10.1364/AO.52.006589.
- [56] de Boer JF, Milner TE, (2002), Review of polarization sensitive optical coherence tomography and Stokes vector determination, *J. Biomed Opt*; 7(3):359-71.

## Tables and figures

### Table 1

In the logistic regression model where the correlation between the two randomized assessments on the same patient is taken into account, the two sided value was 0.0190 when comparing video stroboscopy with high speed films, a statistical higher proportion of patients only with diagnostics with video stroboscopy had treatment involving either voice training or pharmacological treatment with local cortisone/ formeterol inhaler due to less accurate pictures.

	High speed films	Video stroboscopy
Voice training	0/12	5/12
Cortisone/formeterol inhaler	0/12	2/12

**Table 2**

High speed films, comparing dystonia patients with and without low mannose binding lectin, inter-arytenoid region oedema, visual score 2<sup>nd</sup>-1<sup>st</sup> consultation. There was no difference. All dystonia patients were better at the 2<sup>nd</sup> consultation.

	1 <sup>st</sup> consultation			2 <sup>nd</sup> consultation			Change (2 <sup>nd</sup> -1 <sup>st</sup> consultation)			
	N	Mean	Std	N	Mean	Std	N	Mean	Std	p-value
All dystonia patients	55	2.71	0.60	49	2.35	0.63	49	-0.35	0.72	0.0003***
MBL<500 µg/L	26	2.69	0.62	22	2.32	0.57	22	-0.36	0.73	
MBL>500 µg/L	21	2.67	0.58	20	2.30	0.73	20	-0.40	0.75	
MBL<500µg/L vs MBL>500 µg/L										0.90§

§: Test in the linear statistical model where MBL is included as a fixed effect and baseline is included as a covariate.

\*\*\*: Statistically significant on a 0.1% significance level



**Figure 1**

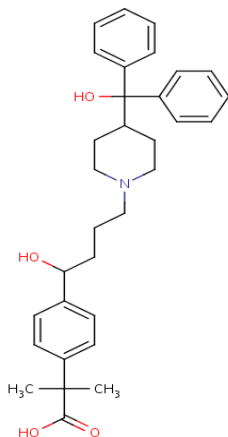
High speed films scores with 4000 pictures per second of the larynx including the arytenoid regions. Score 1 is a normal arytenoid region. Score 3 is presenting a moderate oedema. Score 5, almost total closure of the larynx due to arytenoid oedema (ref 3).

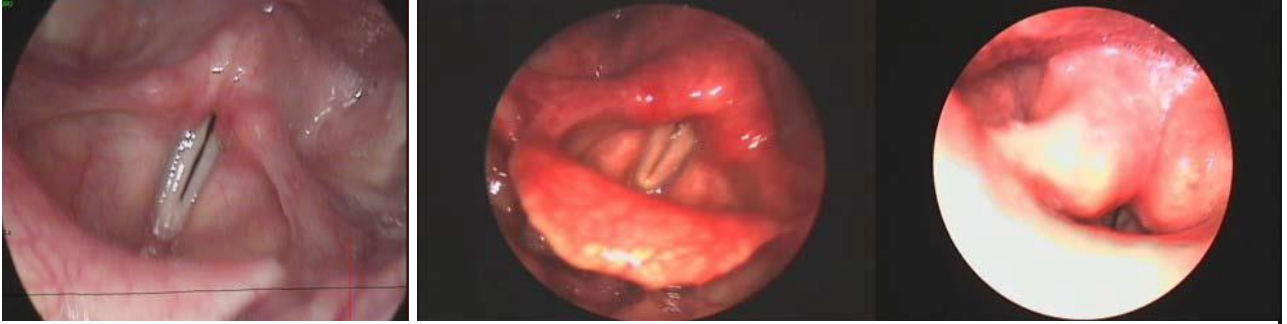

Fig. 1A Score 1	Fig. 1B Score 3	Fig. 1C Score 5
--------------------	--------------------	--------------------

**Figure 2**

### The chemical structure of fexofenadine

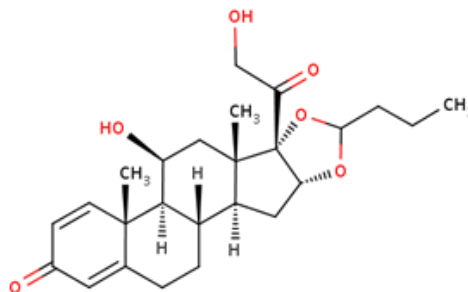


It was developed as a successor of and alternative to terfenadine.

Fexofenadine is a second-generation, long lasting H1-receptor antagonist (antihistamine) which has a selective and peripheral H1-antagonist action. Fexofenadine blocks one type of receptor for histamine (the H1 receptor) and thus prevents activation of cells by histamine. Fexofenadine lacks the cardiotoxic potential of terfenadine, since it does not block the potassium channel involved in repolarization of cardiac cells.

<http://www.drugbank.ca/drugs/DB00950>

### The chemical structure of budesonide

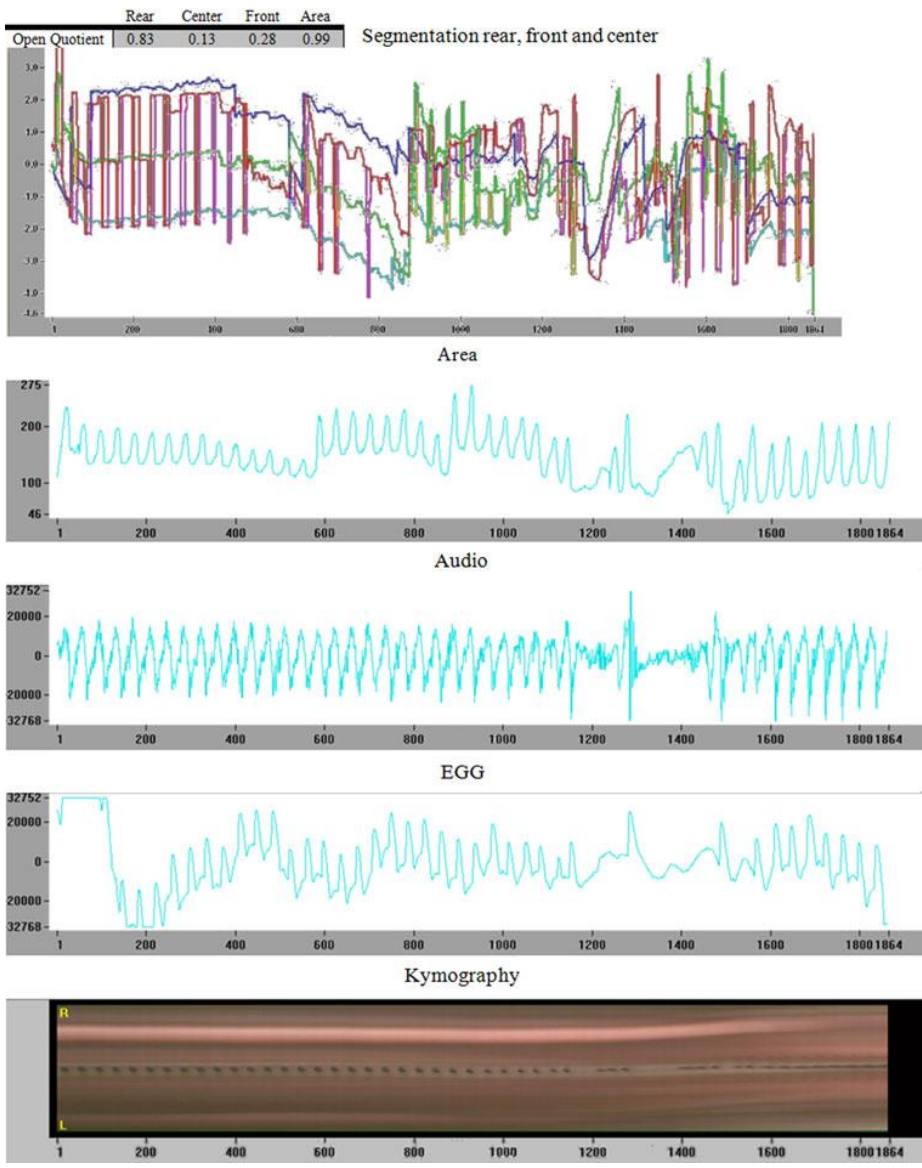


Budesonide has a high glucocorticoid effect and a weak mineralocorticoid effect. It binds to the glucocorticoid receptor with a higher binding affinity than cortisol and prednisolone. Furthermore, a decrease in airway reactivity to histamine and other entities has been observed with the inhaled formulation. Generally, the inhaled formulation has a rapid onset action and improvement can occur within 24 hours of initiation of treatment.

<http://www.drugbank.ca/drugs/DB01222>

### Figure 3

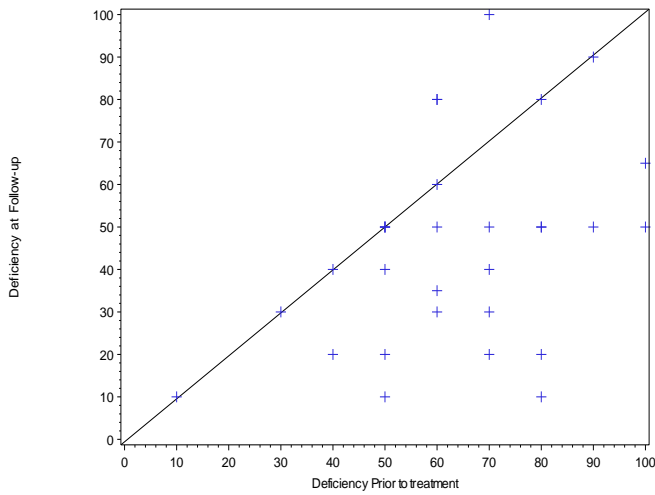
Segmentation curves of high speed film with 4000 pictures per second with calculations of open quotients in the front, center and rear parts of the vocal folds. Visual irregularities are illustrated due to a dystonia spasm—from segmentation curves of the vocal folds in front, center and rear parts. Area between the vocal folds during intonation, acoustical-, electroglottographical-, and kymographical curves are also presented (ref 6).



**Figure 4**

- a) Shows that the whole spasmodic patient population was better at the follow up on treatment with fexofenadine and local budesonide inhaler in the larynx for the symptom deficiency.
- b) Mean change on quality on life.

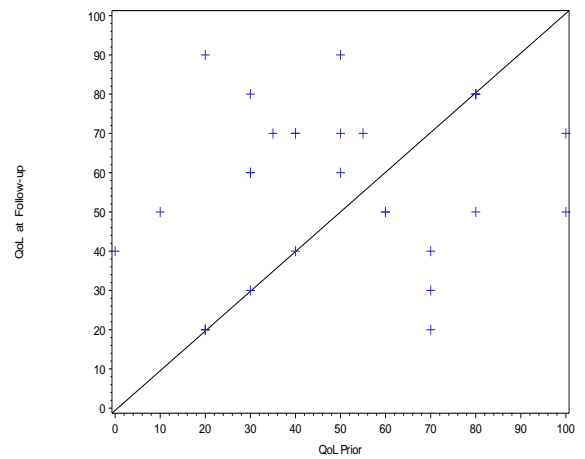
Scatter plot - Deficiency self assessment



VSSolutions - Generated 30MAR11/scatter\_deficiency.cgm

- a) Mean change from prior assessment to follow up assessment of -18.3 ( $p=0.0001$ ). 95% CI: [-27; -10]. 0=no sickness, 100=very sick.

Scatter plot - Quality of Life



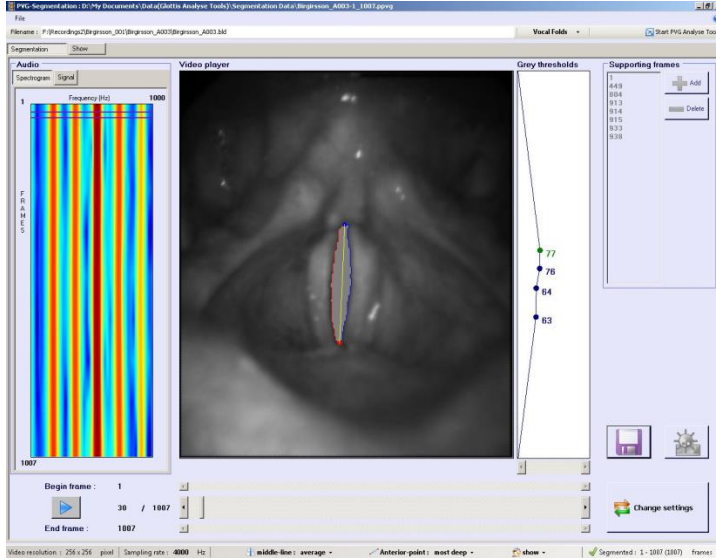
VSSolutions - Generated 30MAR11/scatter\_qol.cgm

- b) Mean change from prior assessment to follow up assessment of 7.3 ( $p=0.072$ ). 95% CI: [-0.7; 15]. 0=worst possible quality, 100=best possible quality of life.

**Figure 5**

The Glottis Analysis Tool, for advanced quantitative software analysis of high speed films.

A



A shows the imported recording and the segmentation in Glottis Analysis Tools (M Döllinger). The possibilities are many to ensure an accurate segmentation: varying black/white balance and segmentation area during the length of the film are just some of them.

B Glottal Analysis Tools along moving high speed films. An increased control with contrast ensures accurate segmentation, and the area is calculated in each vocal fold cycle. This also ensures accurate jitter, shimmer and opening quotients. (Pubertal singing soloist, boy)

B

Shimm(%)	5,048				
HNR(dB)	11,098				
Jitt (%)	0,542				
		Mean	Std	Min	Max
ClosingQuotient(CQ)	0,4149	0,0602	0,2727	0,5455	
AsymmetrieQuotient	0,4872	0,0721	0,3333	0,5833	
Stiffness	Left	0,4919	0,1902	0,254	0,9897
Stiffness	Right	0,4769	0,1664	0,2625	0,8411

