

Electroglottography Compared with Synchronized Stroboscopy in Normal Persons^{1, 2}

M. Fog Pedersen

ENT Department, Gentofte University Hospital, Hellerup

Introduction

During the past years intensive studies have been performed to develop the objective registration of the movements of the vocal chords (*Titze and Strong, 1975; Sondhi, 1975*).

Fabre (1957), Michel (1967), Holm (1970), Reinsch and Gobsch (1972), Fourchin (1974), Pedersen and Boberg (1973), and Pedersen (1974) have performed studies with electroglottography. *Kitamura et al. (1967), Hertz et al. (1970)* and many others tried to describe the ultrasonic recordings of vocal fold vibrations. Among others, *Sonesson (1960)* and *Kitzing and Sonesson (1974)* described coefficients for the photoelectric picture of the movements of the vocal chords.

Köster and Smith (1970) concluded that electroglottography is a most relevant method to describe the phases of the vocal chord in the chest register. *Michel et al. (1970)* have compared the opening and the closing phases of the vocal chord in electroglottography with high-speed films. *Fourchin (1974)* compared the electroglottography with photos of stroboscopic movements and discussed the problems of using this method in a clinical setting. *Lecluse et al. (1975)* tested the glottographs on excised human larynxes and found correspondence between glottograms and the movements of the vocal chords.

¹ Paper read at the 8th World Congress of Phonetics, Leeds 1975.

² Statistics performed with assistance from the Danish Research Fund.

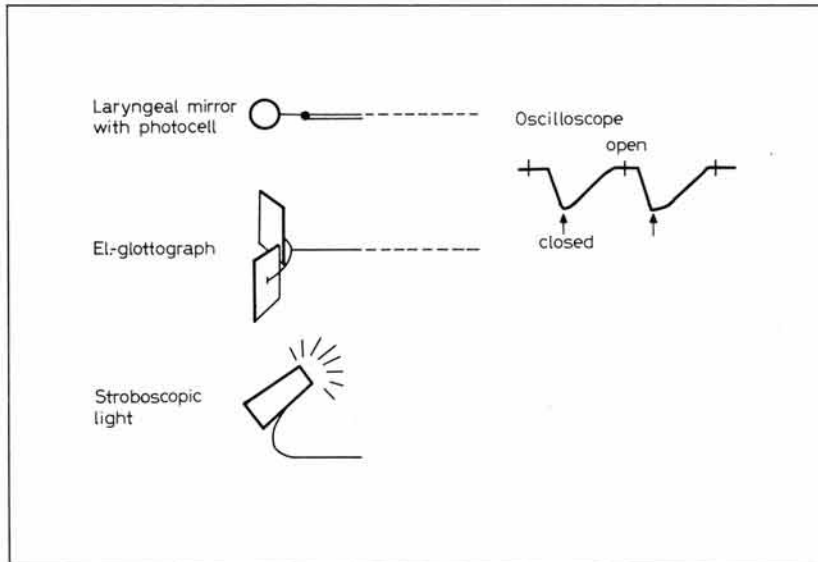


Fig. 1. Experimental set-up: stroboscope, larynx mirror with attached photocell, electroglottograph and oscilloscope.

The intention of this work was an objective registration of the stroboscopic examination (Schönhärl, 1960). The evaluation of the glottographic curve is difficult. In this study, the electroglottographic curves were used only for registration of the stroboscopic picture, and marking of the phases was done with a photocell. It was then possible to plot the variations in the curves. Measurement of coefficients for opening and closing phases was possible in those cases where the glottographic curve could not be used alone to define these coefficients. Thereafter, quantitative measurements of hyper- and hypofunctional diseases (Wendler *et al.*, 1973) as well as organic disorders of the vocal chords should be possible.

Method

The examination was carried out with a glottograph (FJ Electronics, type 830), a stroboscope (Thiemcke, type KS 3), a sound level meter (Brüel & Kjær, type 2205), and an oscilloscope with polaroid camera. A photocell attached to a larynx mirror was connected to the oscilloscope (fig. 1).

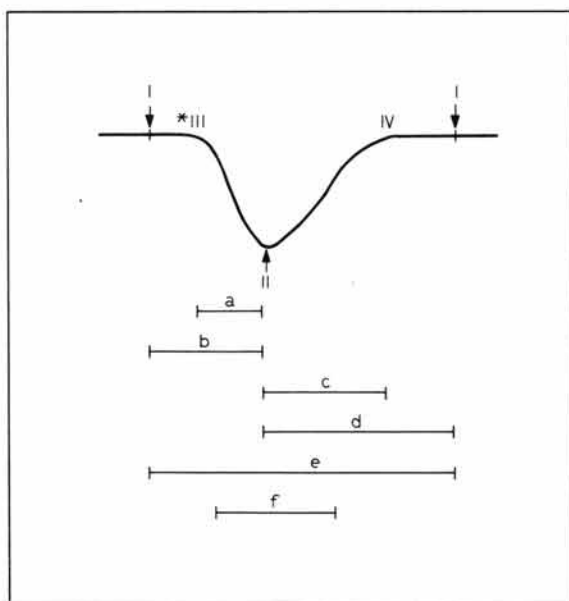


Fig. 2. Point I is the maximum opening phase and point II is the maximum closing phase in the stroboscope, marked on the electroglottography. III and IV are the changes from the plateau to the slope on the glottographic curves. Various quotients are defined (see text).

At first, pictures were made with different time scales to record suitable electroglottographic curves when received from the electrodes on the throat during intonation. The picture on the oscilloscope was shown as sweeps with appropriate amplitude. Hereafter, the intensity of the sound pressure in front of the throat was measured in relation to the background noise. The examination was carried out in a standard examination room of the ENT department with a background noise of 38–42 dB. When the stroboscope was in use, the background noise was around 50 dB. During stroboscopy the light glimpses from the photocell were shown in the maximum closing phase. The Thiemcke stroboscope emitted a suitable light for fixation of the phase in the larynx mirror. The mirror with a photocell marked the maximum closing phase on the glottography. After having photographed the closing phase, the examination was repeated with the maximum opening phase.

Figure 2 shows the maximum opening (point I) and closing (point II) phases. Points III and IV are the changes from the plateau to the slope of the glottographic curves.

The time from point III to point II is called 'a'. 'b' is the whole closing phase. 'c' is the time from point II to point IV. 'e' is the whole cycle. 'd' is the whole opening phase, and 'b' and 'd' correspond to the stroboscopic findings. 'f' is the closing phase described by the inverse tangent of the slope.

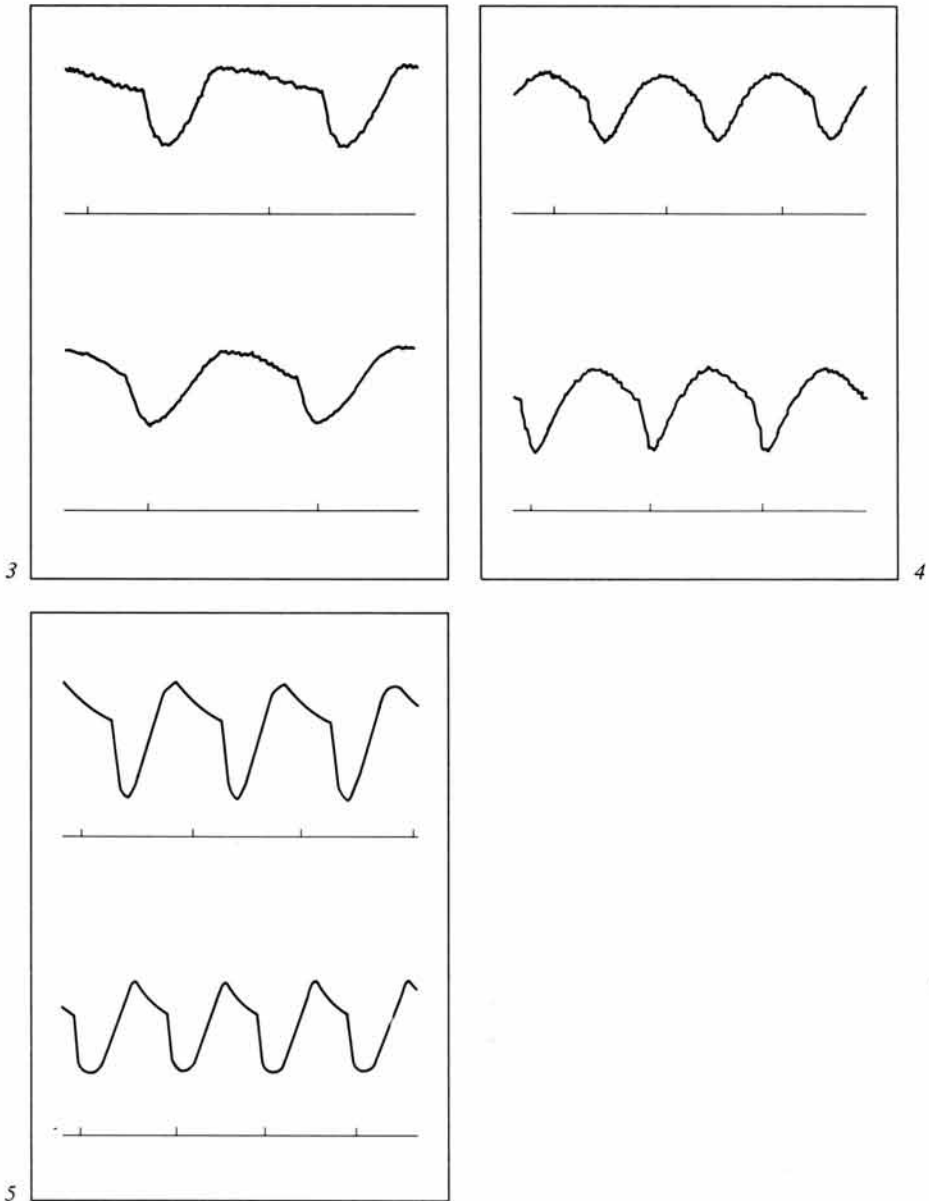


Fig. 3-5. Examples of the variation of the glottographic curves in persons with normal stroboscopy. The markings of the stroboscopic picture for maximum opened and closed phases are seen.

Mean values and deviations for the coefficients have been calculated: A (= a/e), B (= a/b), C (= c/e), and D (= c/d). Calculations have also been computed for the mean values of the whole closing phase (b), the opening phase (d), and 'f'.

All values and coefficients have been calculated for every person. Mean values and mean coefficients were calculated from these averaged values. The correlation calculations were obtained from the co-variance matrix correlation coefficient analysis.

Material

The subjects consisted of 20 employees of the hospital, 14 females and 6 males. They were used to evaluate the glottographic curve in relation to the stroboscopic picture.

The subjects had never suffered from voice problems. The function of the voice was normal with respect to the stroboscopic picture. The intensity was around 68–72 dB. The respiration was abdominal or mixed abdominal/costal in all persons. The frequency of speech was 200–220 Hz for women and 100–110 Hz for men.

The persons intoned an 'a' sound with their usual basic frequency. 'a' was used because it is the most commonly used vocal in examinations with a larynx mirror.

Results

No differences were seen between the curves for men and women. The examination was very simple and did not give technical problems, although an average of half of the persons became tired from the long duration of the laryngoscopy.

The movements of the vocal chords in normal persons gave variations from person to person in the glottographic curves. Figures 3–5 show examples of the variations. After marking of the closing phase, 70% showed a maximum point in the bottom of the curve of the closing phase. The maximum closing phase was constant over the duration of the half-hour examination.

To evaluate the clinical use, a statistical analysis was performed among the different glottographic coefficients to find uniform data. The results of the analysis for mean values and deviations are seen in figure 6. The coefficients A and C had the smallest variations, with deviations for A and C in the 95% confidence limits of 2.9–18.1% and 18.7–48.9%, respectively.

For the remaining coefficients, deviations from mean values were approximately 50%. This was also the case for the calculation of the closing phase defined by the inverse tangent of the slope. No correlation was found between the different coefficients calculated by comparing all values.

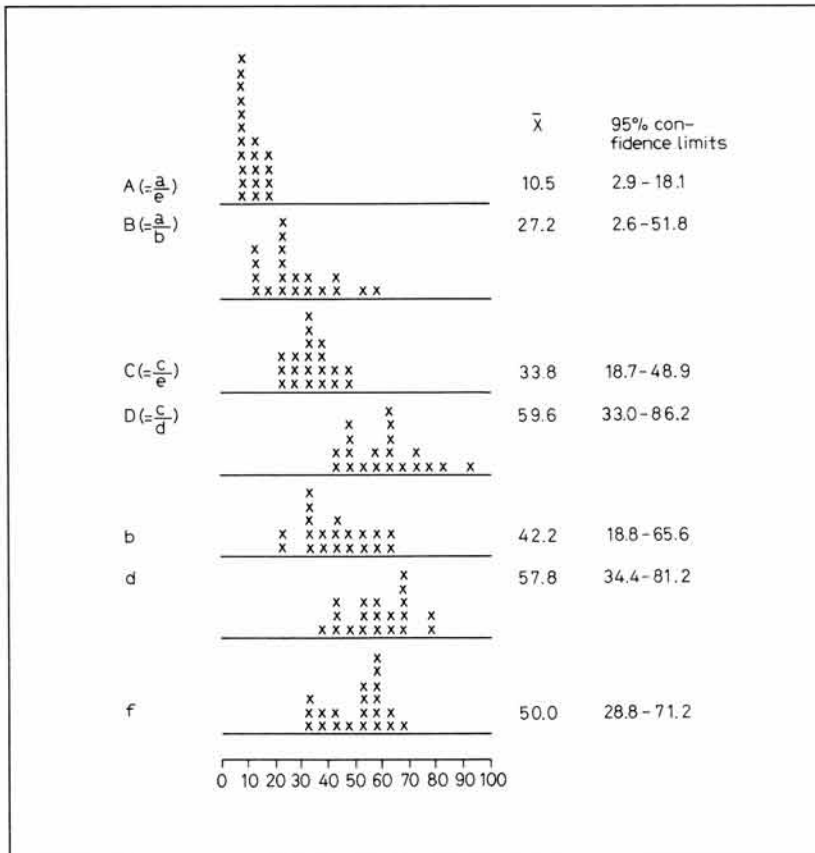


Fig. 6. Result of the analysis for mean values and deviations of the opening and closing phases, and coefficients (fig. 2). Variations of the closing phases and of the opening phases in relation to the whole cycle (= A and C) were smaller than those of the other values.

Discussion

The problems concerning electroglottography concentrate on the apparatus, evaluation of the curves, and the possible practical use.

The use of the glottograph is not so difficult in the practical clinic. We are currently constructing a foot pedal so that the photographs of the maximum opening and closing phases can be performed more quickly.

Measurement of the AC-coupling distorts the curve so that the closing phase is less well defined. If the maximum opening and closing phases are marked stroboscopically, no distortion is calculated in the time of the described coefficients. It is possible with glottography to use DC-coupling although the curve cannot yet be stabilized on the oscilloscope.

Glottography has not been used in the clinical work for quantitative evaluation of voice disorders due to the lack of certainty when describing the phases. *Sonesson* (1960) and *Reinsch and Gobsch* (1972) have divided the curves in a way that cannot be utilized for evaluation of pathologic voices or of normal voices in which the voice parameters were not optimal. When the curves are seen in relation to the stroboscopic examination, evaluation of the relationship and duration of the phases can be performed with greater certainty.

Beach and Kelsey (1968) and *Holmer et al.* (1973) have encountered difficulties with the use of glottography, probably because of the complex movement pattern of the vibrating vocal folds. Large deviations were found between the phases of the curve in our study, but the quantitative descriptions in normal persons are still regarded as a progressive step. It is now possible to evaluate pathologic voices quantitatively from a normal material. Patients with organic voice disorders, i.e., tumors, seem to be outside the normal ranges. Functional voice disorders lie in the borderline, but quantitative calculations must be made for the various disorders together with a quantitative division in the variations of the phases.

It is, of course, expected that a logopedic treatment changes a glottographic curve of the patient towards an optimum for the different phases. Measurements are therefore desired on singers for the duration and variation of the phases. Other persons with optimal voices could also be used. It is our impression that a simultaneous quantitative acoustical analysis of the voice also could be helpful for determining the borderline cases of normal and/or optimal voice.

Summary

A marking of the stroboscopic picture on electroglottographic curves was performed on 20 normal persons. The maximum opening and closing phase was marked by a photocell on the glottographic curve, the photocell following the glimpses from the stroboscope. The duration of the opening and closing phases were calculated together with the slopes of the opening and closing phases. The closed phase, defined by the inverse tangent of the slope, was also measured. The calculations were computed, and no correlation was found between the durations of the phases. The variations in the material were very large. In order to

calculate the phases with greater accuracy, an examination on singers would be of value. Calculation of the duration of the phases together with their variations from curve to curve would also be valuable.

References

- Beach, J.L. and Kelsey, C.A.*: Ultrasonic doppler monitoring of vocal-fold velocity and displacement. *J. acoust. Soc. Am.* 46: 1045–1047 (1968).
- Fabre, P.*: Un précode électrique percutané d'inscription de l'accolement glottique au cours de la phonation: glottographie de haute fréquence. Premiers résultats. *Bull. Acad. natn. Méd.* 121: 66 (1957).
- Fourchin, A.J.*: Laryngographic examination of vocal fold vibration. An International Symposium of Ventilatory and Phonatory Control System, p. 315 (Oxford University Press, London 1974).
- Fourchin, A.J. and Abberton, E.*: First application of a new laryngograph. *Med. biol. Illust.* 21: 172–182 (1971).
- Hertz, C.H.; Lindström, K., and Sonesson, B.*: Ultrasonic recording of the vibrating vocal folds. *Acta oto-lar.* 69: 223 (1970).
- Holm, C.*: Erste Ergebnisse einer Elektroglottographie im Kindesalter (Kongressbericht). *Arch. klin. exp. Ohr.-Nas.-KehlkHeilk.* 196 (1970).
- Holmer, N.-G.; Kitzing, P., and Lindström, K.*: Echo glottography. Ultrasonic recording of vocal fold vibrations in preparations of human larynges. *Acta oto-lar.* 75: 454–463 (1973).
- Kitamura, T.; Kaneko, T.; Asano, H., and Miura, T.*: Ultrasonoglottography. A preliminary report. *Med. Ultrason.* 5: 40–41 (1967).
- Kitzing, P. and Sonesson, B.*: A photoglottographical study of the female vocal folds during phonation. *Folia phoniatic.* 26: 138–149 (1974).
- Köster, J.-P. und Smith, S.*: Zur Interpretation elektrischer und photoelektrischer Glottogramme. *Folia phoniatic.* 22: 92–99 (1970).
- Lecluse, F.L.E.; Beoccar, M.P., and Verschuure, J.*: The electroglottography and its relation to glottal activity. *Folia phoniatic.* 27: 215–224 (1975).
- Michel, C. van*: Morphologie de la courbe glottographique dans certains troubles fonctionnels du larynx. *Folia phoniatic.* 19: 192–202 (1967).
- Michel, C. van; Pfister, K.A. et Luchsinger, R.*: Electroglottographie et cinématographie laryngée ultra-rapide. *Folia phoniatic.* 22: 81–91 (1970).
- Pedersen, M.F.*: Clinical investigations of patients with benign tumors of the larynx before and after microlaryngoscopy. 16th Int. Congr. Phoniatics Logopedics, Interlaken. *Folia phoniatic.* 26: 184–185 (1974).
- Pedersen, M.F. and Boberg, A.*: Examination of voice function of patients with paralysis of the recurrent nerve. *Acta oto-lar.* 75: 372–374 (1973).
- Reinsch, M. und Gobsch, H.*: Zur quantitativen Auswertung elektrogloggographischer Kurven bei Normalpersonen. *Folia phoniatic.* 24: 1–6 (1972).
- Schönhärl, E.*: Die Stroboskopie in der praktischen Laryngologie (Thieme, Stuttgart 1960).

- Sondhi, M.M.*: Measurement of the glottal waveform. *J. acoust. Soc. Am.* 57: 228–232 (1975).
- Sonesson, B.*: On the anatomy and vibratory pattern of the human vocal folds. With special reference to a photo-electrical method for studying the vibratory movements. *Acta oto-lar., suppl.* 156 (1960).
- Titze, I.R. and Strong, W.J.*: Normal modes in vocal cord tissues. *J. acoust. Soc. Am.* 57: 736–744 (1975).
- Wendler, J.; Seidner, W.; Rose, A.; Simon, B. und Ulbrich, H.*: Zur praktischen Nomenklatur der funktionellen Dysphonien. *Folia phoniatic.* 25: 30–38 (1973).